

## Behandling Höftledsluxation

- Varför?
- von Rosen skena i 12 veckor
- Bad en gång per vecka
- Läkbesök 4-6 veckor beh.
- En månad efter avslutad beh. Klinisk och radiologisk kontroll.
- 15 månaders ålder klin. och radiologisk kontroll.

---

---

---

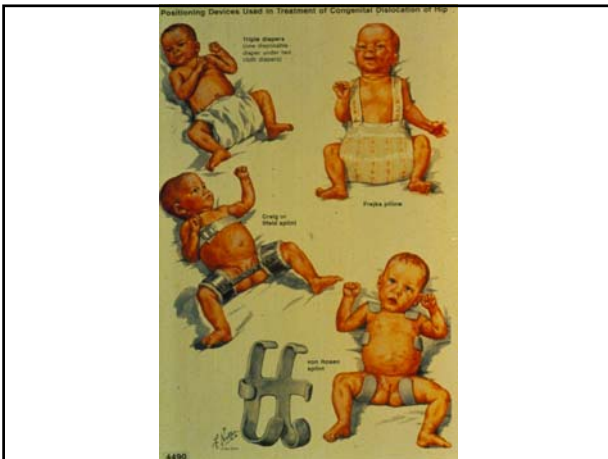
---

---

---

---

---



---

---

---

---

---

---

---

---

## Behandling Höftledsluxation

- Sent upptäckta behandlas ofta med sträck i ca tre veckor därefter artrografi och sluten eller öppen reposition samt gips.
- Äldre barn ibland bäckenosteotomi.

---

---

---

---

---

---

---

---

## Idiopatisk Scolios

- Flickor, vanligast i 10-15 års åldern
- Screening i skolan
- Mäter rotationen med scoliometer
- Rtg visar Cobbvinklar

---

---

---

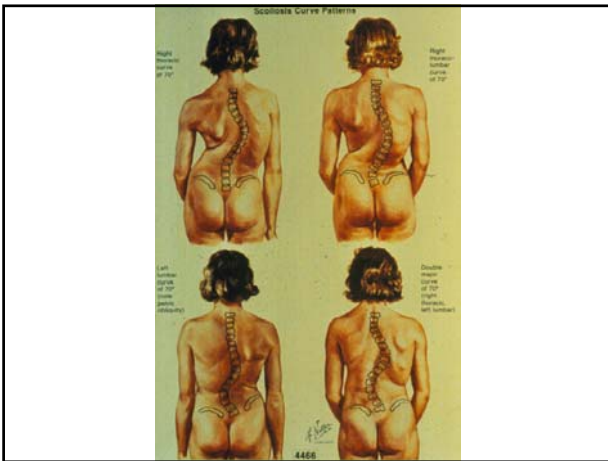
---

---

---

---

---



---

---

---

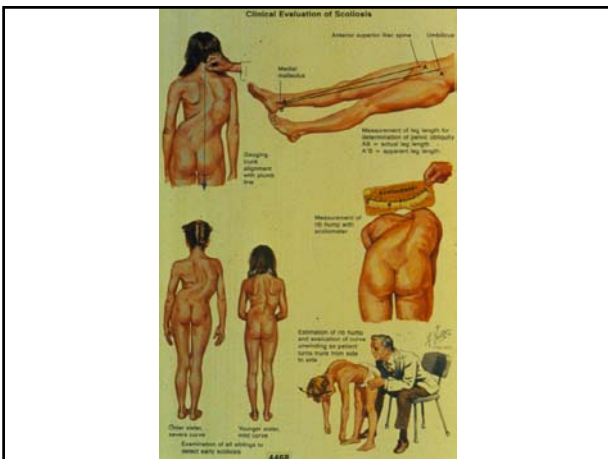---

---

---

---

---



---

---

---

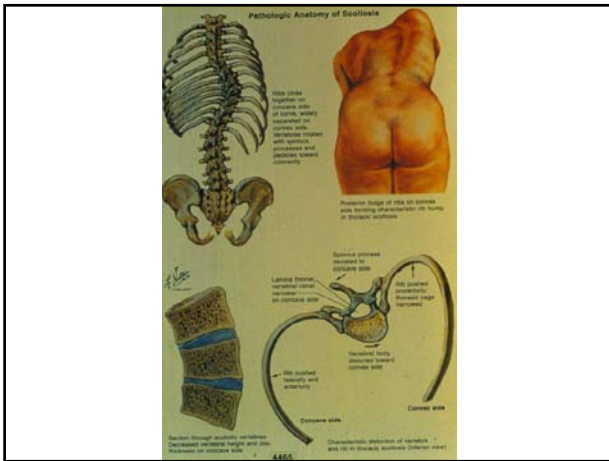
---

---

---

---

---




---

---

---

---

---

---

---

---

### Scolios behandling

- < 25 grader Observation
- >25 grader Korsettbehandling
- >45 grader Operation

---

---

---

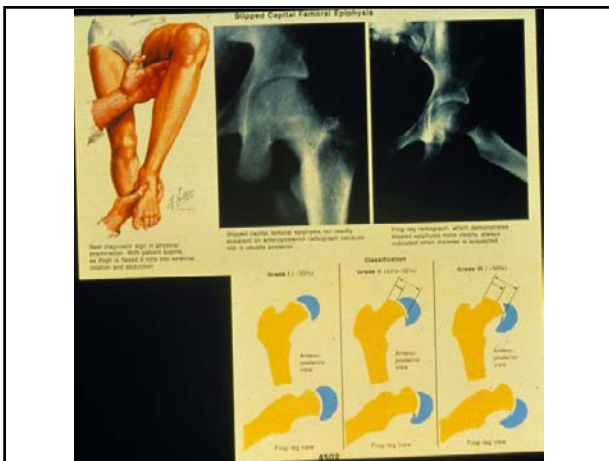
---

---

---

---

---




---

---

---

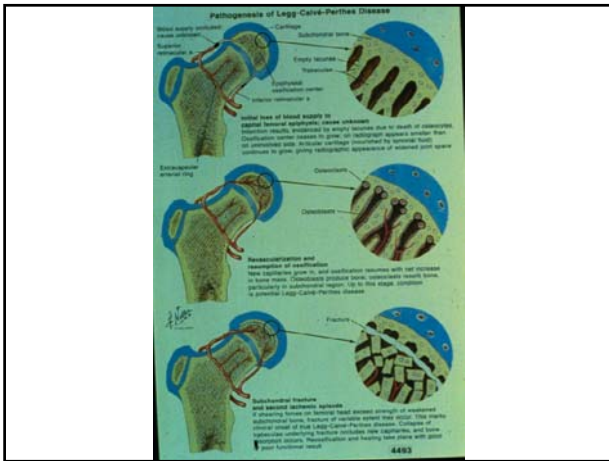
---

---

---

---

---




---

---

---

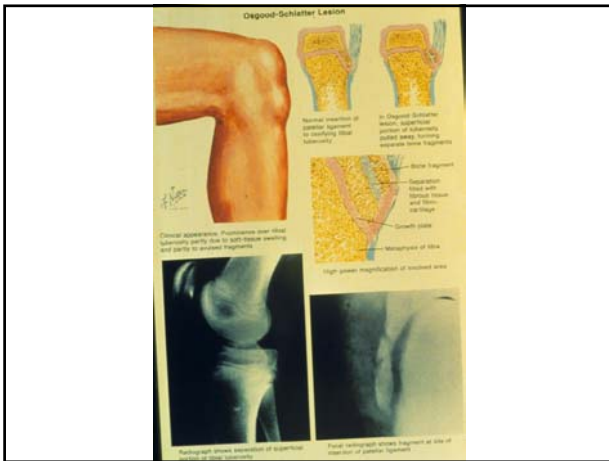
---

---

---

---

---




---

---

---

---

---

---

---

---

I ortopediska sammanhang är ett barn en individ med öppna tillväxtzoner

---

---

---

---

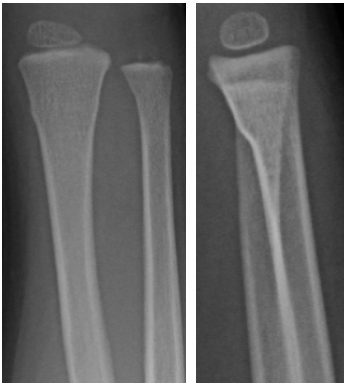---

---

---

---

Infraktion



---

---

---

---


---

---


---

---

Normal underarm



Pilbågsfraktur



---

---

---

---

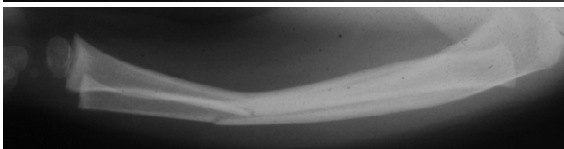
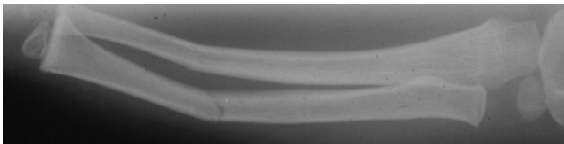
---

---

---

---

Green-stickfraktur



---

---

---

---

---

---

---

---