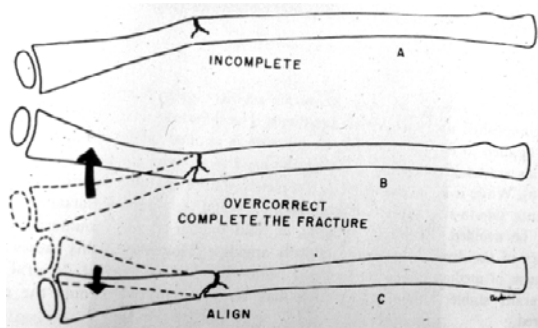


### Reposition av green-stickfraktur



---

---

---

---

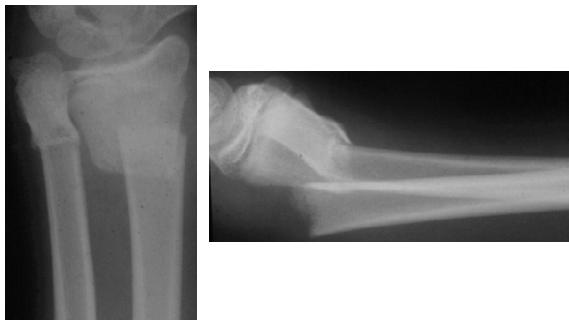---

---

---

---

### Distal metafysär underarmsfraktur



---

---

---

---

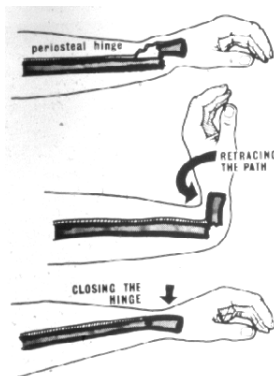
---

---

---

---

### Reposition vid bajonettföreställning



---

---

---

---

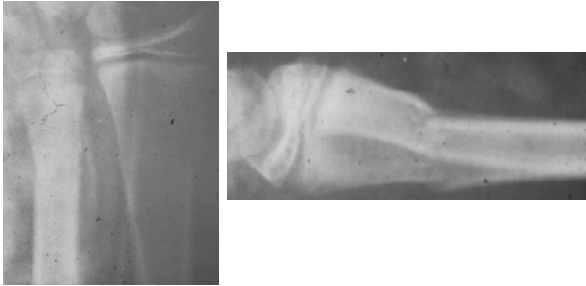
---

---

---

---

Reponerad distal radiusfraktur



---

---

---

---

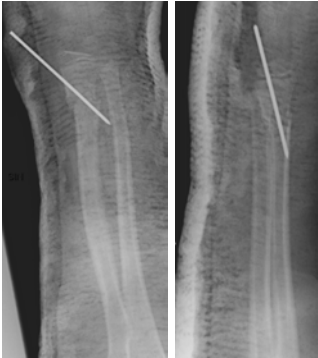---

---

---

---

Stiftning av metafysär fraktur



---

---

---

---

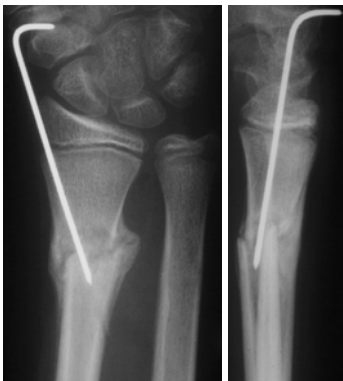---

---

---

---

Stiftning av metafysär fraktur



---

---

---

---

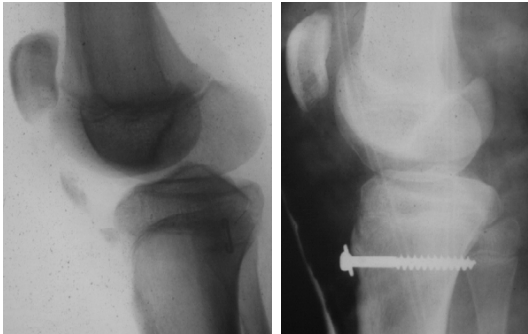
---

---

---

---

Avulsion av tuberositas tibiae



---

---

---

---

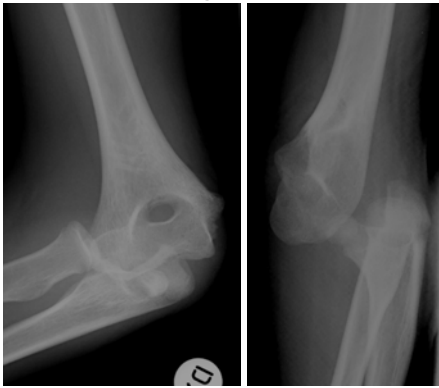
---

---

---

---

Armbågluxation



---

---

---

---

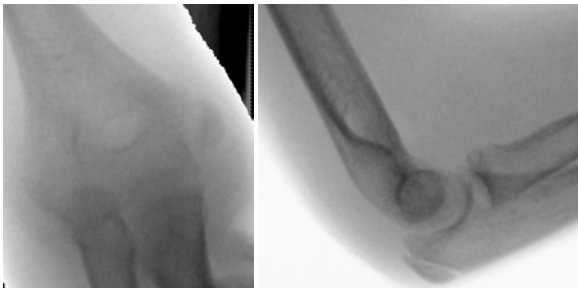
---

---

---

---

Reponerad armbågluxation



---

---

---

---

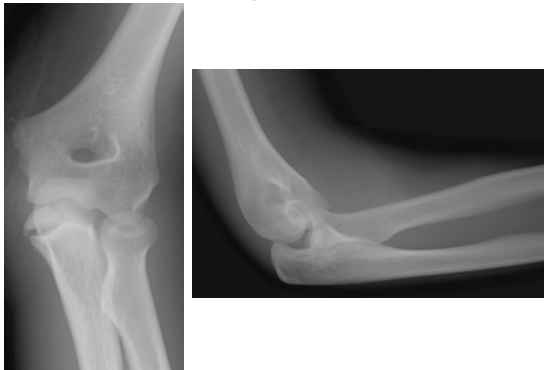---

---

---

---

### Armbågsluxation



---

---

---

---

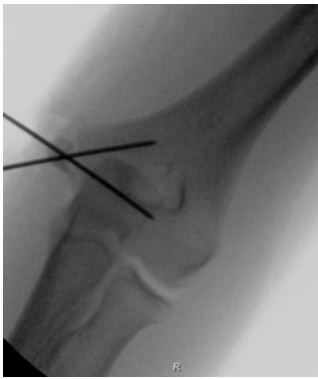
---

---

---

---

### Reponerad armbågsluxation



---

---

---

---

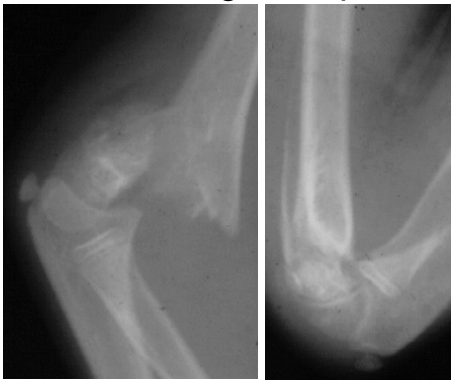
---

---

---

---

### Periostegenskaper



---

---

---

---

---

---

---

---